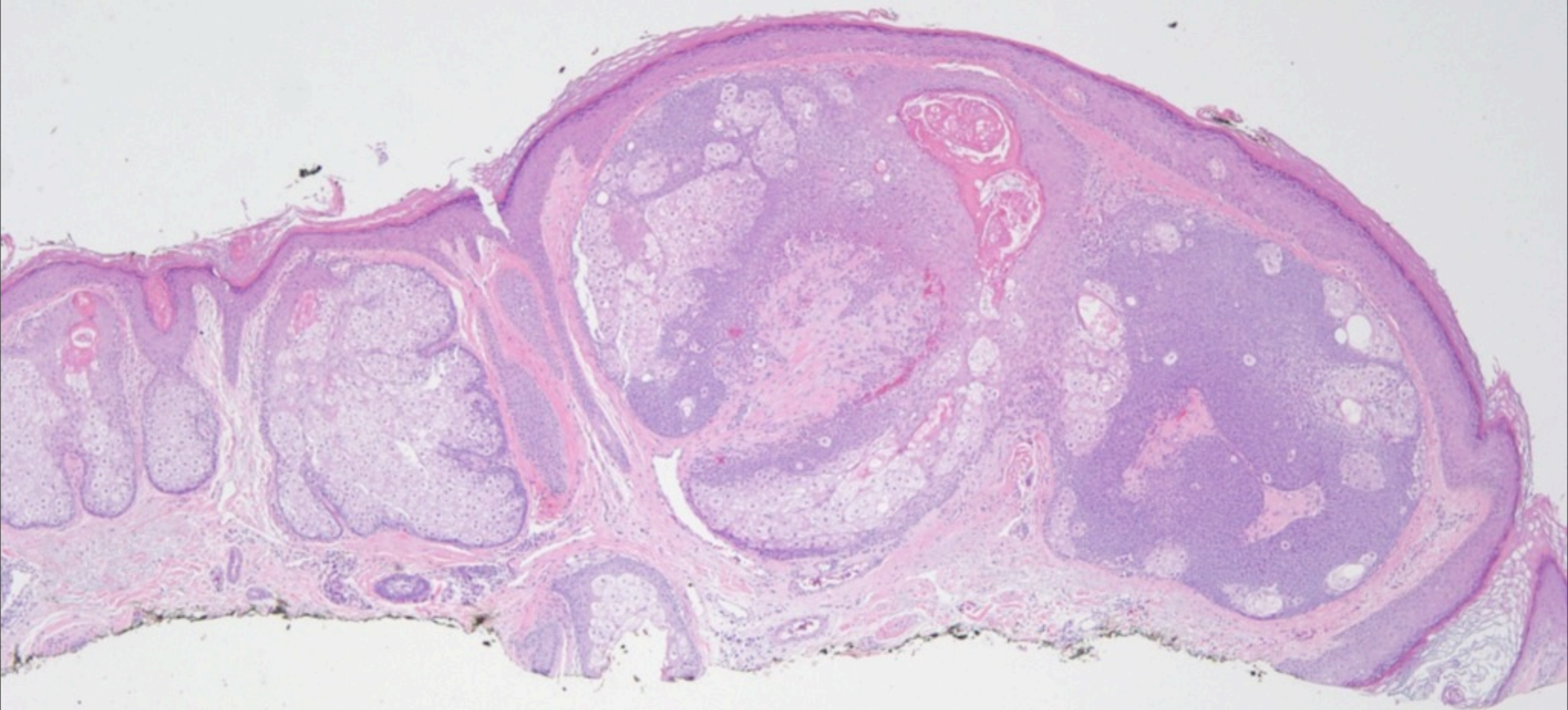
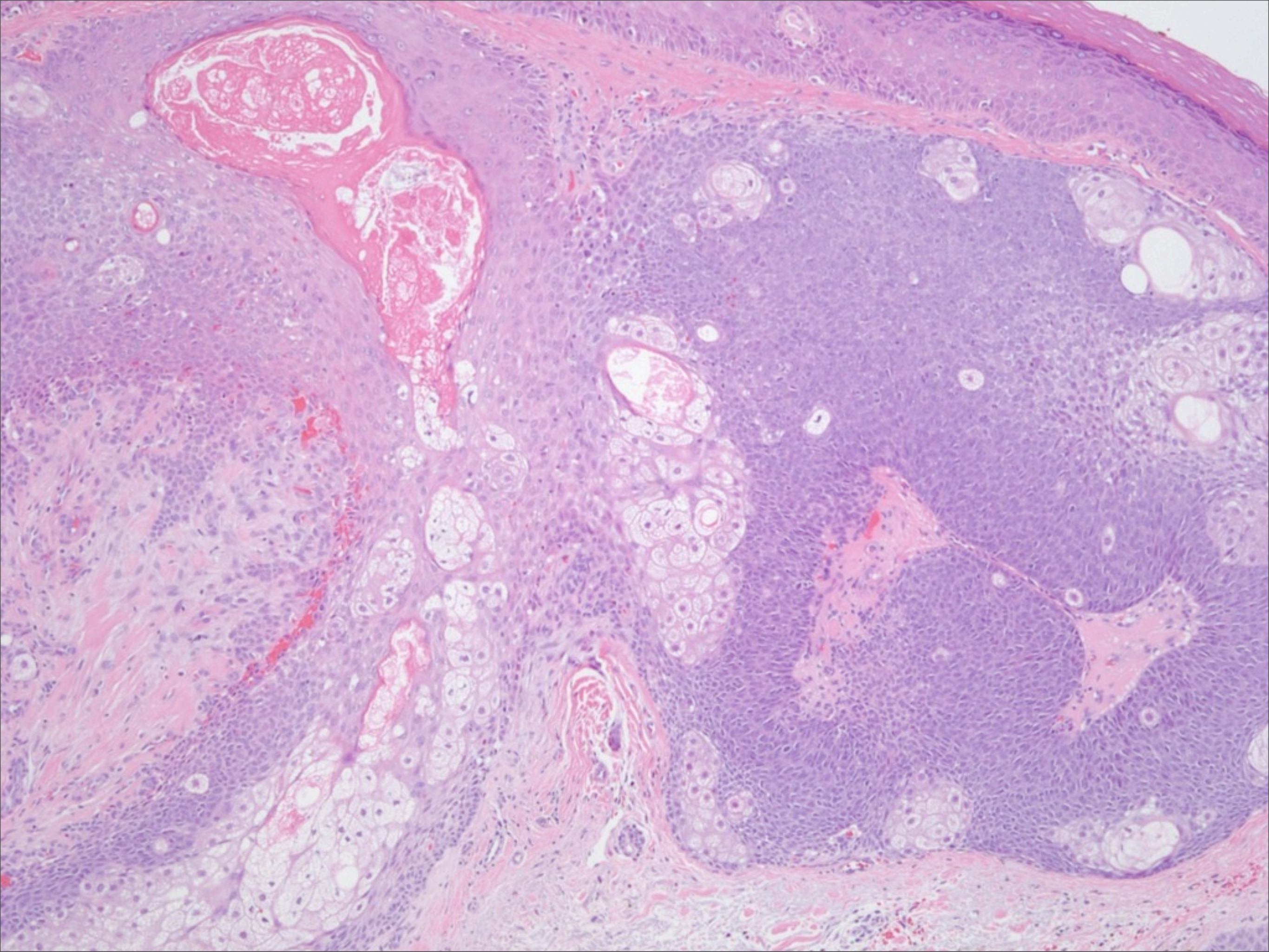
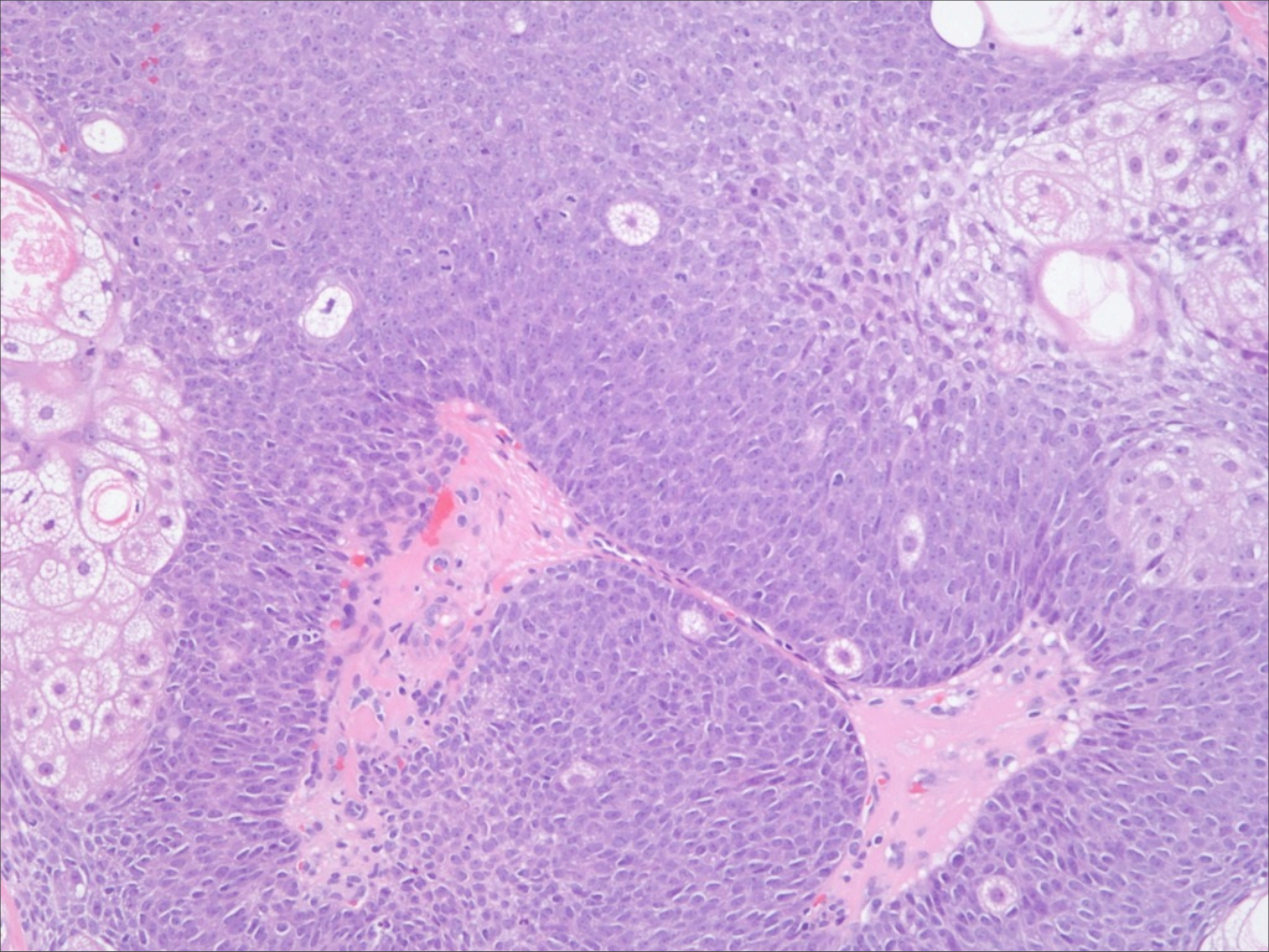

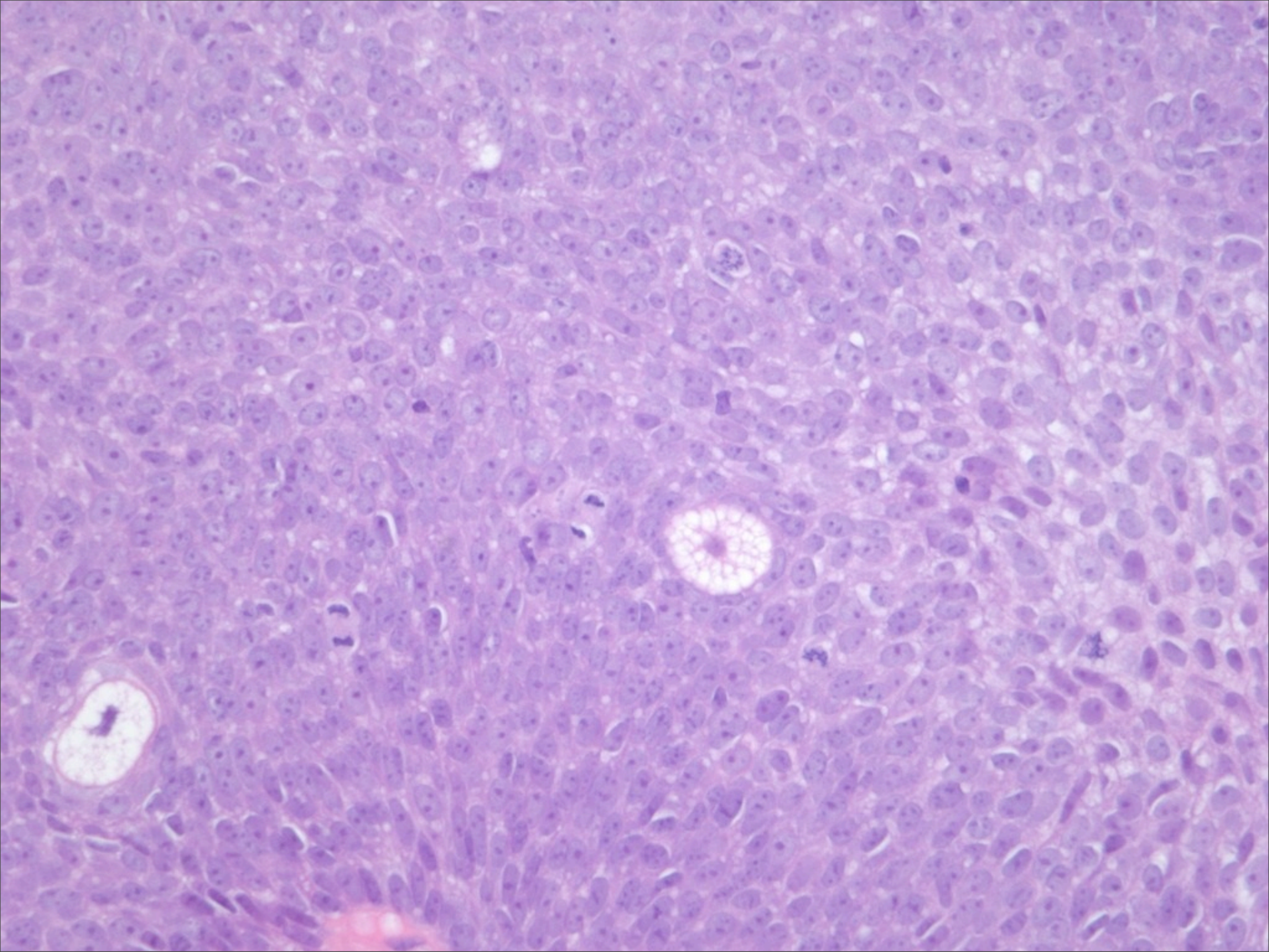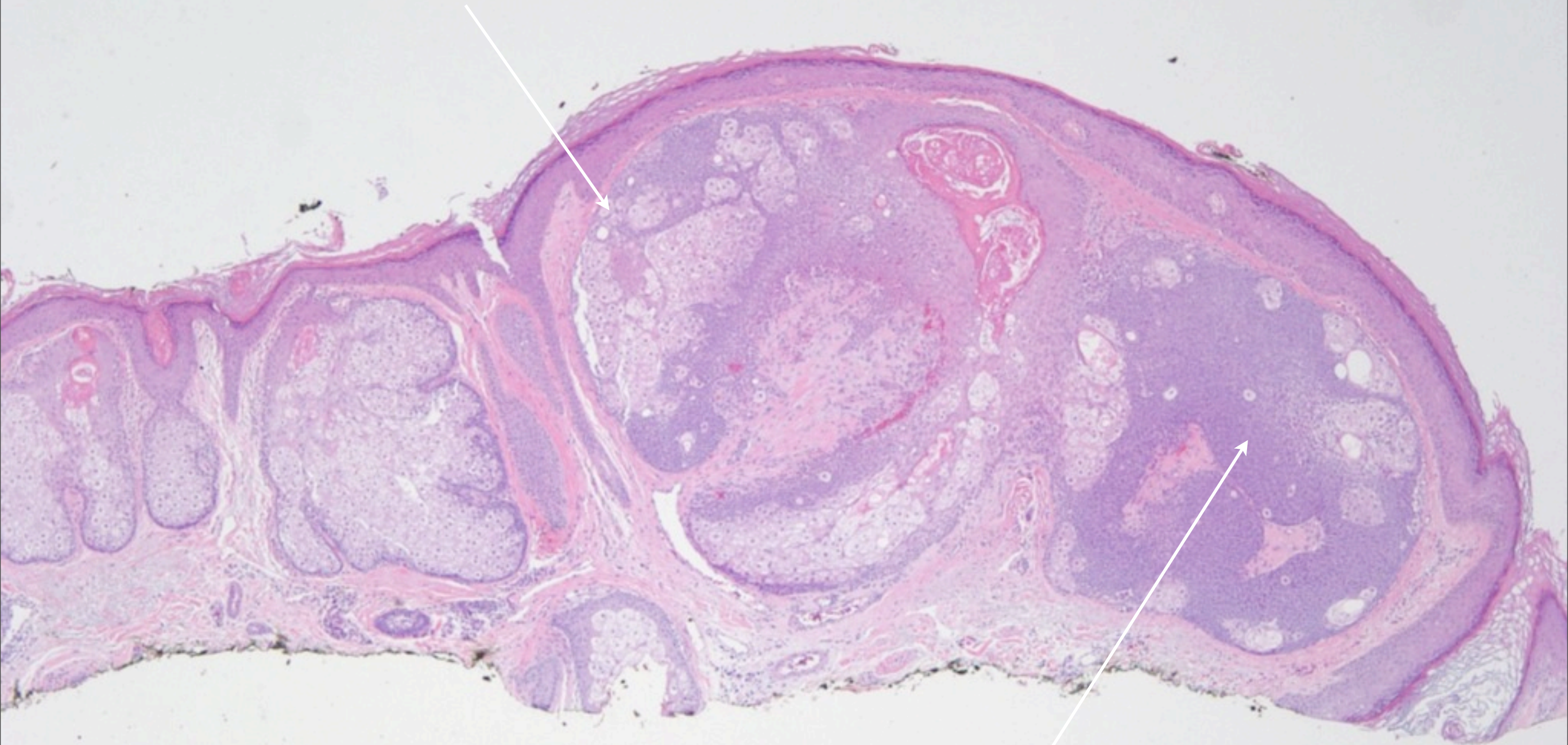
# What is the best diagnosis?

- Sebaceous Carcinoma
- Basal Cell Carcinoma with Sebaceous Differentiation
- Sebaceoma
- Sebaceous Gland Hyperplasia
- Eccrine Poroma with Sebaceous Differentiation

# Sebaceoma



Circumscribed nodules of basaloid cells



Sebocytes haphazardly scattered  
in varying stages of maturation